

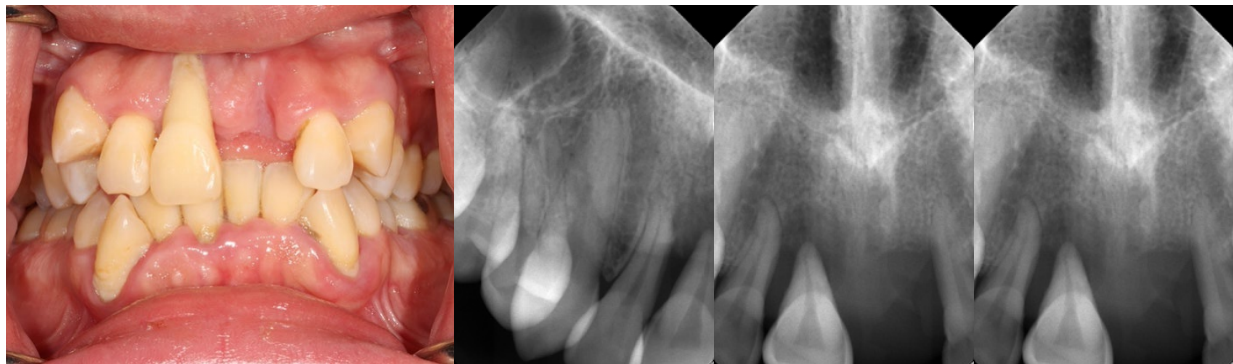
Fellowship Examination Prosthodontics: Sample Case


Disclaimer

The following sample case is provided for illustrative purposes only. It is intended to demonstrate the style of case presentation and the type of reasoning expected in the Fellowship Examination. It should not be taken as a reflection of the specific content, scope, or level of difficulty of the actual examination.

Case Scenario

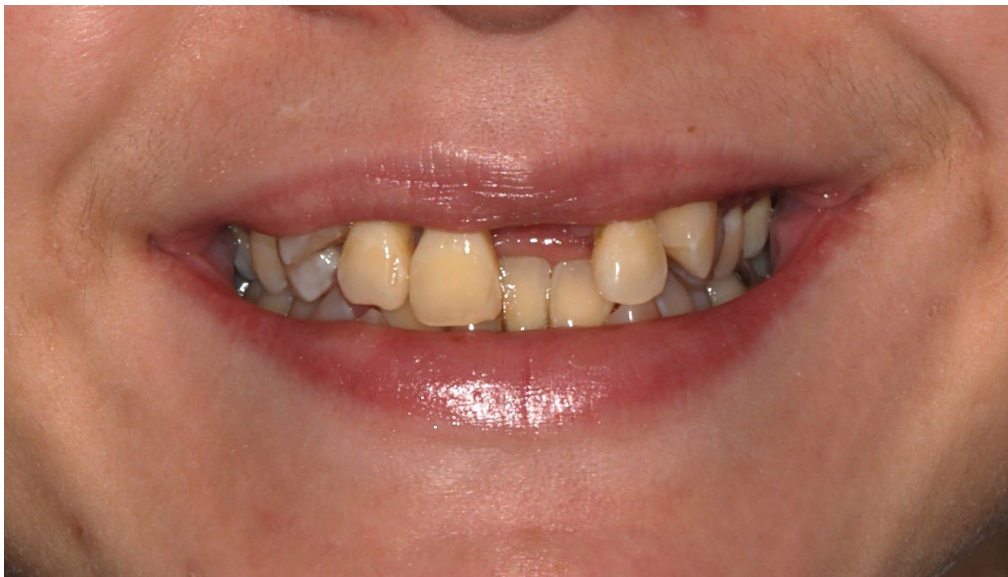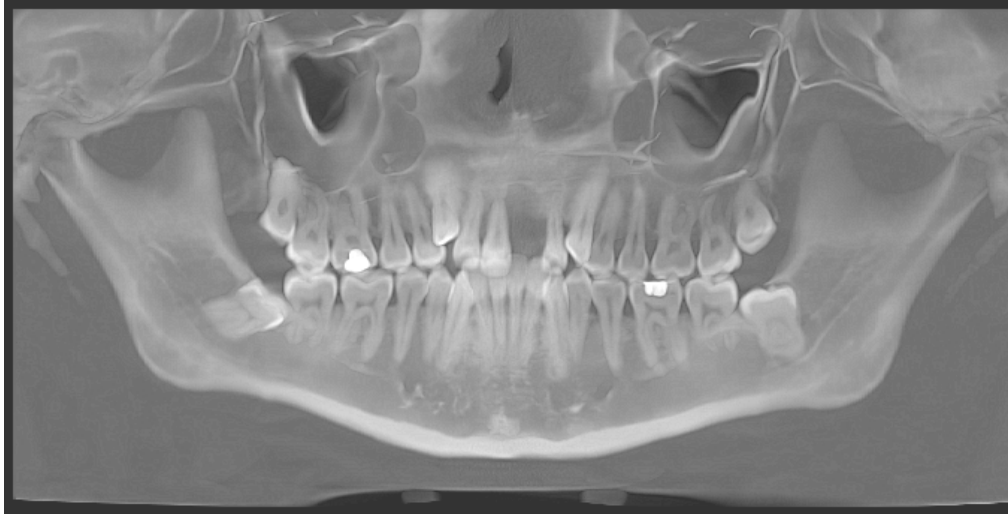A 24-year-old patient presents with a chief complaint of having lost 2.1 and she has been unhappy with her smile.





RCDC


THE ROYAL COLLEGE OF DENTISTS
OF CANADA



Data Gathering and Diagnosis

Question What would you discuss with the patient regarding her esthetic concerns?

Question: What are your restorative concerns for this patient?



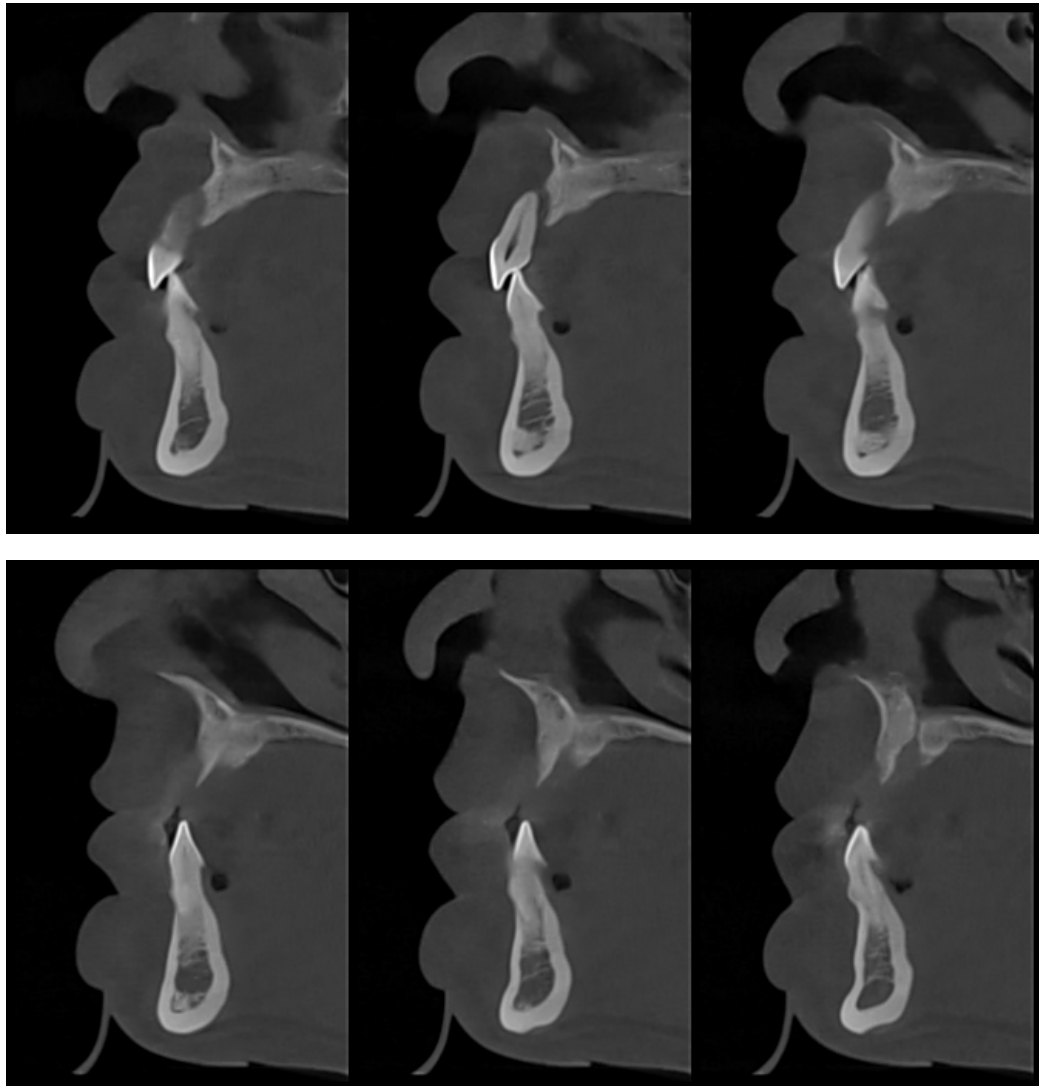
RCDC


THE ROYAL COLLEGE OF DENTISTS
OF CANADA

Treatment Planning and Management

Question: What treatment options would you discuss with the patient.

Question: Which treatment option would provide the most predictable esthetic outcome?





RCDC

THE ROYAL COLLEGE OF DENTISTS
OF CANADA

Maintenance, Complication Management, and Alternative Care

Question: What procedures might be necessary to maximize implant survival and esthetic outcome?

Communication

Candidates are assessed on communication holistically throughout the case.